

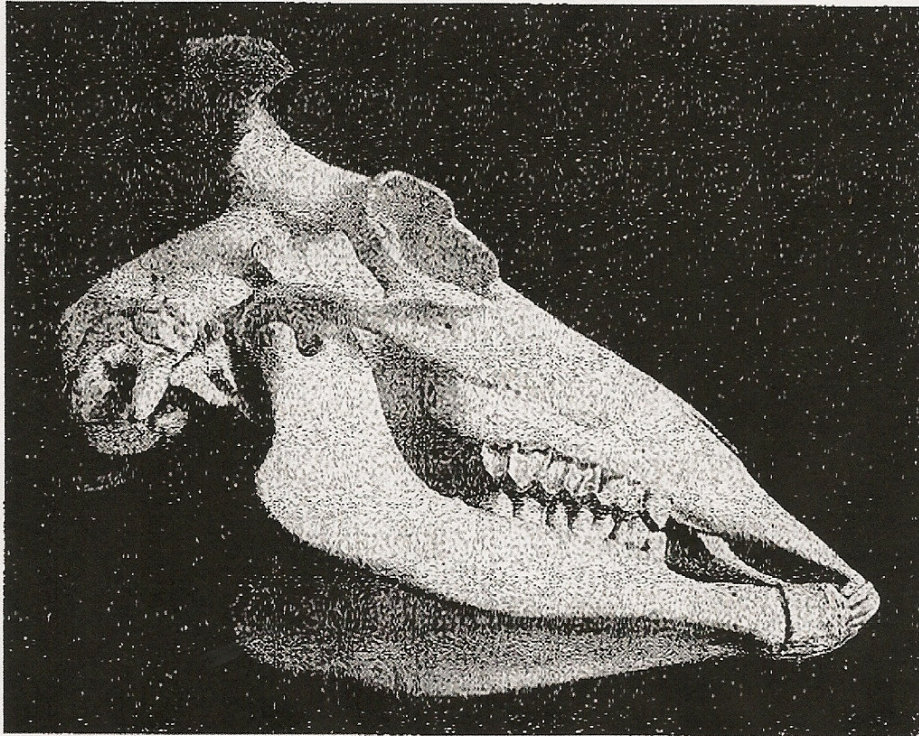Fig. 83.  
Upper and Lower Jaws of a Normal Animal.

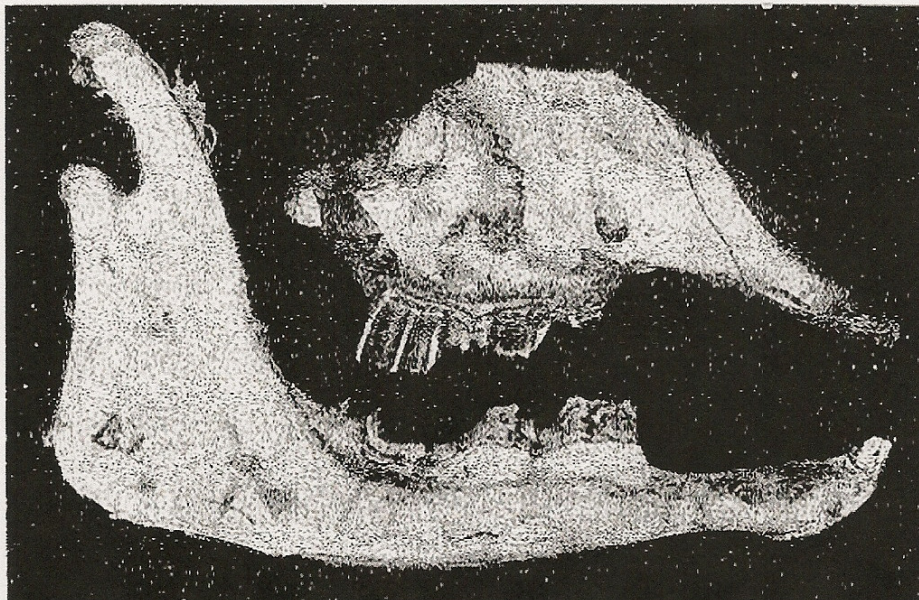


Fig. 84.  
Abrasion of the Molars and Premolars of Sheep Using Water Containing 5-7 p.p.m. Fluorine and Depastured on Hard Mitchell Grass Country. Note the compensatory wear on the upper and lower molars and premolars.